

# A tooth preparation technique in fixed prosthodontics for students and neophyte dentists

Daniele Rosella, DDS<sup>1</sup>  
 Giancarlo Rosella, MD, DDS<sup>2</sup>  
 Edoardo Brauner, DDS, PhD<sup>1</sup>  
 Piero Papi, DDS<sup>1</sup>  
 Luca Piccoli, DDS, PhD<sup>1</sup>  
 Giorgio Pompa, MD, DDS<sup>1</sup>

<sup>1</sup> Department of Oral and Maxillofacial Sciences, "Sapienza" University of Rome, Italy

<sup>2</sup> Private Practitioner, Italy

## Corresponding author:

Daniele Rosella  
 Department of Oral and Maxillofacial Sciences, "Sapienza" University of Rome  
 Via Caserta 6  
 00161 Rome, Italy  
 E-mail: daniele.rosella@gmail.com

## Summary

**Purpose.** The aim of this study was to evaluate a novel technique of tooth preparation in fixed prosthodontics suitable for dental students and neophyte dentists.

**Materials and methods.** Twenty-four dental students of the sixth-year class were recruited to verify the predictability of this technique. Each student prepared two mandibular second premolars on a typodont for a dental crown with a 90° shoulder finishing line. One tooth was prepared using standard procedures taught in the prosthodontic dental course; the other tooth was prepared with the new technique. Three Professors of Prosthodontics of the same University evaluated the result on the basis of 10 criteria.

**Results.** A statistically significant difference between the two techniques was found in 8 out of 10 criteria. The new technique showed higher values ( $p < 0.05$ ) in 7 criteria, while the conventional technique had better results in just 1 criterion. Moreover, the total sum of values was higher for the new technique (total  $41.2 \pm 3.98$ ,  $p < 0.05$ ) compared to the conventional technique (total  $38.12 \pm 5.18$ ,  $p < 0.05$ ).

**Conclusions.** This study showed that the results were less dependent on manual abilities and per-

sonal experience with the novel technique. It could help dental students and neophyte dentists in their learning curve.

**Key words:** tooth preparation, fixed prosthodontics, dental education, prosthodontics.

## Introduction

Tooth preparation for fixed prosthesis is a common procedure in clinical practice, which all general dentists should perform correctly. However, it could be difficult to obtain always a predictable result, especially for dental students or young doctors: they could make mistakes in their learning curve leading to inadequate results.

Unlike other human substance, dental tissues don't have regenerative capacity. Therefore, the removal of dental biological material should be planned and executed with maximum attention (1).

The purpose of a fixed prosthodontic therapy may vary from the restoration of a single tooth to the rehabilitation of the complete occlusion. A single tooth can be fully restored both functionally and aesthetically. A missing tooth can be replaced by a fixed prosthesis, increasing patient masticatory competence and maintaining or improving dental arches function, often elevating patient's self-image (2).

Tooth preparation should have specific geometrical characteristics to provide necessary retention and resistance to the vertical and lateral forces acting on the restoration. The most important element of retention is the presence of two opposing vertical surfaces. The axial walls of the preparation should taper slightly to allow the cementation of the artificial crown. The more parallel are the axial walls the greater is the retention. However, it is impossible to obtain parallel surfaces without producing undercuts. Goodacre et al. (3) suggest an angle of convergence between 10 and 20°. Moreover, the occlusocervical length is another fundamental factor for both retention and resistance. The longer is the preparation the greater is the retention. Teeth with larger diameter need a greater length to prevent dislodgement (4). Proper occlusal and axial reductions are essentials to provide enough space, allowing a good functional morphology and structural durability. Moreover, no more than necessary dental tissues should be removed in order not to jeopardize tooth structure and retention of the restoration (2).

Preston (5) and Miller (6) suggest starting the tooth preparation producing depth-orientation grooves on the vestibular and incisal surfaces, with a round-end tapered diamond as reference for removing tooth structure. The occlusal reduction is performed by removing the tooth por-

tions between the orientation grooves with the same bur. After the functional cusp bevel is made, a no. 17L bur is used to smooth the planes of the occlusal reduction. Three vertical grooves are performed in the vestibular surface with a flat-end tapered diamond. All tissues between the depth-orientation channels are removed. The proximal reduction is performed with a needle narrow diamond, avoiding damage to the adjacent teeth. The lingual and proximal surfaces are then cut with a torpedo diamond (2). Different finishing line may be created. A chamfer is considered the preferred choice for veneer metal restoration. Several Authors have shown how this finishing line exhibits the least stress, with the lowest failure rates (7). A shoulder finishing line is used for all-ceramic crowns, minimizing stresses with its wide and preventing the possibility of the porcelain fracture. However, it is the more destructive finishing line for the tooth tissues. On the other hand, the knife-edge is the more conservative finishing line, but it may result in an over-contoured restoration.

The most demanding challenges for prosthodontists are the control of depth and direction of tissue removal. None of the Authors in the current literature had proposed a systematic procedure in which every bur of the previous step produces a stopping surface on the tooth for the next one.

The aim of this paper is to present a novel technique of tooth preparation in fixed prosthodontics, capable to decrease the importance of dentist's manual skill in order to obtain a proper result.

## Methods

### Novel technique

The new technique consists of *six burs* (Fig.1):

- *Bur N°1*: diamond-coated depth marker of 1 mm with a round and flat stopping surface;

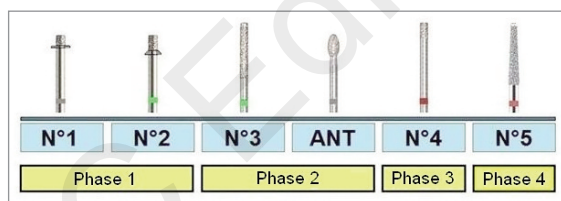


Figure 1. Burs and phases of the novel technique.

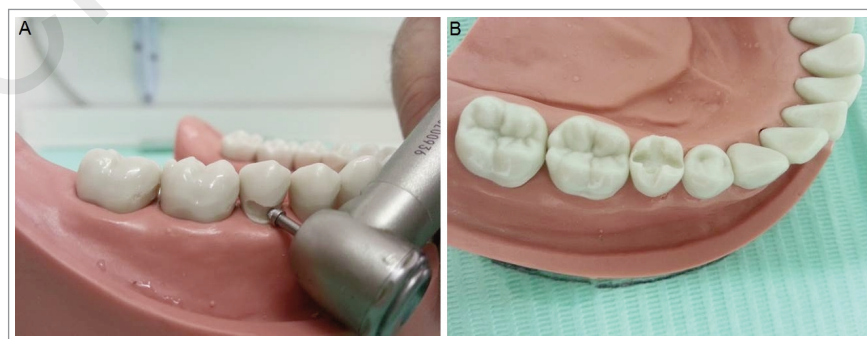


Figure 2. A, Depth-orientation groove placed with the N°1 bur along the vestibular gingival margin of a mandibular second premolar. B, Longitudinal and transversal deep guide channels on the occlusal surface made with the N°2 bur.

- *Bur N°2*: diamond-coated depth marker of 2 mm with a round and angled stopping surface;
- *Bur N°3*: cylindrical diamond of 1 mm with no diamond head;
- *Bur ANT*: football diamond bur. It is the only one conventional bur of the kit;
- *Bur N°4*: cylindrical bur with the only 2 final mm diamond-coated;
- *Bur N°5*: truncated cone diamond bur with no diamond head.

The innovation of this technique is the easier control of depth and direction of the removing procedures. Indeed, due to flat and no diamond-coated stopping surfaces, the dentist can dominate easier the bur during tooth reduction. Every bur tracks a guide for the following one. There are less variables to consider, so the error-probability is lower.

The technique consists in *four phases* (Fig. 1):

1. *First phase*: axial and occlusal reduction depths
2. *Second phase*: reduction
3. *Third phase*: finishing line preparation
4. *Fourth phase*: tooth surface refining.

#### 1. Axial and occlusal reduction depths

Depth-orientation grooves are placed with the N°1 bur along the vestibular and oral gingival margin of the tooth (Fig. 2A). The round and flat stopping surface of the bur doesn't allow to go beyond a depth of 1 mm.

*Anterior teeth*: two or three grooves are completed on the incisal surface with the N°2 bur.

*Posterior teeth*: following the tooth occlusal anatomy, the dentist creates longitudinal and transversal deep guide channels on the occlusal surface with the N°2 bur (Fig. 2B). The angled stopping surface of the bur makes it easier between the cusps. It doesn't allow the dentist to go deeper than 2 mm.

#### 2. Actual reduction

##### 2.1 Incisal/occlusal reduction

*Anterior teeth*: the tooth incisal reduction is made between the grooves with the N°3 bur.

*Posterior teeth*: the no diamond head of the N°3 bur is placed at the bottom of the central sulcus on the

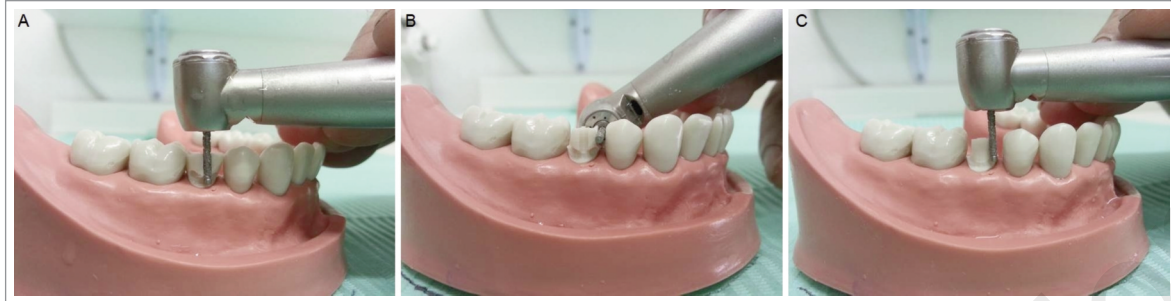

Figure 3. A, Vestibular view of a deep guide groove made with the N° 3 bur. B, Interproximal reduction made with the N° 3 bur orientated perpendicularly to the major axis of the tooth. C, Circumferential axial reduction.

occlusal surface. The occlusal reduction is made using as reference the trasversal deep guide channels. An uniform reduction of 2 mm is easily obtained just moving the bur in the mesiodistal way.

## 2.2 Axial reduction

An axial deep guide groove is made with the N° 3 bur. It should be directed in a perfectly vertical way and in parallel with the tooth major axis. The no diamond head doesn't allow to remove dental tissue beyond the 1 mm depth of the gingival margin groove (Fig. 3A). The same bur is used to separate the tooth from the proximal one. The interproximal cut is made with the N° 3 bur orientated perpendicularly to the major axis of the tooth (Fig. 3B). If it isn't possible, or the dentist prefers an approach to the interproximal cut in the

convention way, it could be practicable to start using a normal flame bur.

The N° 3 bur could now easily remove the axial circumferential surface through the reference of the axial and the cervical grooves (Fig. 3C).

The ANT bur is used in the anterior teeth only to reduce the occlusal area between the cingulum and the incisal margin.

## 3. Finishing line preparation

The N° 4 bur is used to prepare the finishing line. The smooth proximal portion of the bur allows to use the axial surfaces of the cast to guide the dentist in the preparation (Fig. 4).

## 4. Tooth surface refining

The N° 5 bur refines the tooth surface. It is used to round the line angle of the stump and eliminates any undercut (Fig. 5A, B).

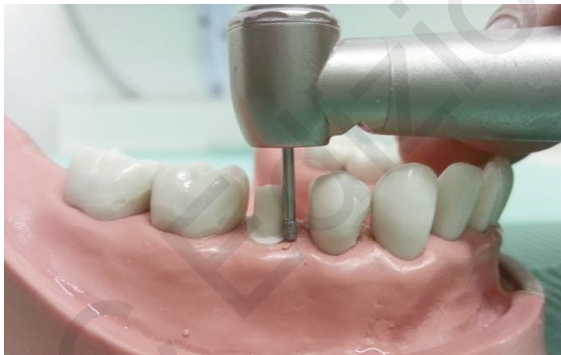

Figure 4. Vestibular view of the 90° shoulder finishing line made with the N° 4 bur.

## Study sample selection

Twenty-four students of the 6<sup>th</sup> years dental school were recruited to test the novel technique. They volunteered for the study by responding to an email sent to the sixth-year class. All participants gave verbal and written consent to take part of the study, according to the World Medical Association's Declaration of Helsinki.

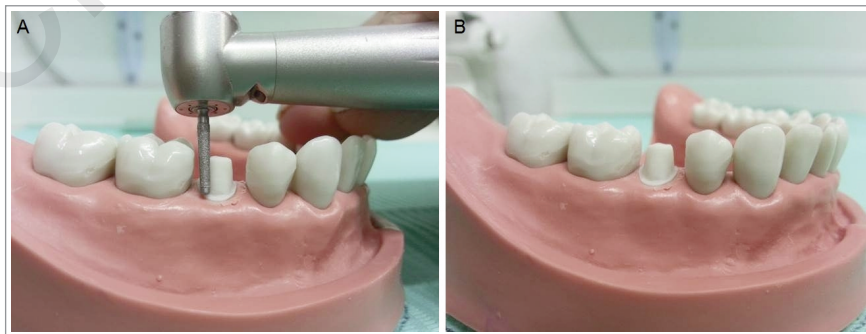


Figure 5. A, Refining procedures made with the N° 5 bur. B, Final vestibular view of a mandibular second premolar prepared with the novel technique.

Each student prepared two mandibular second premolars (#4.5) on a typodont for a dental crown with a 90° shoulder finishing line. One tooth was prepared using standard procedures (1, 2) taught in the prosthodontic dental course; the other tooth was prepared with the new technique. Prior to the beginning of the study, the students were given a thirty-minute training session on how to use the novel technique with the first Author, DR.

Three Professor of Prosthodontics (SDC, GP and LP) of the same University evaluated the result on the basis of 9 scientific principles described by Goodacre et al. (3).

1. *Total occlusal convergence (TOC):*  
TOC is the angle of convergence formed between the two opposite axial surfaces of the preparation; it should vary between 10 and 20°.
2. *Occlusocervical dimension:*  
The minimal size of incisors and premolar prepared with 10-20° of TOC is 3 mm (8). 4 mm is the minimal dimension of molars prepared within 10-20° of total occlusal convergence (9).
3. *Ratio of occlusocervical/incisocervical dimension to faciolingual dimension:*  
For all teeth it should be 0.4 or higher (4).
4. *Circumferential morphology:*  
Everytime is possible, facioproximal and linguoproximal corners of the teeth should be preserved (10).
5. *Finish line location:*  
Whenever possible, a supragingivally finish lines should be preferred (11-19); when subgingival finish lines are required, they should preserve the epithelial attachment (20-22).
6. *Finish line form and depth:*  
A chamfer finish lines of 0.3 mm is deep enough for all-metal crowns (23, 24). The different finish line chosen for use with metal-ceramic crowns should not be related to marginal fit but on personal preference (25, 26). Although metal-ceramic finish line depths of 1.0 mm or more is recommended, the optimal depth has not been determined. Both chamfer and shoulder can be used with all-ceramic crowns bonded to the prepared teeth (27, 28). A greater depth than 1 mm is not necessary when a semitranslucent type of all-ceramic crown is used (29).
7. *Axial and occlusal reduction depths*  
All-metal crowns should be reduced at least 0.5 mm on the axial surface and 1.0 mm on the occlusal surface. For metal-ceramic crowns, axial reductions beyond 1 mm can prejudice the residual tooth structure external to the pulp (30); a 2.0 mm of occlusal reduction is generally possible even on a young tooth (2, 23, 24, 31). With all-ceramic crowns, it is not required a greater depth than 1 mm of axial reduction and 2 mm incisal/occlusal reduction with semitranslucent systems (29).
8. *Line angle form:*  
Line angles of tooth preparations should be rounded to reduce stress in the restoration (31-

33). It also facilitate pouring impressions and investing wax patterns without trapping air bubbles and to ease removing casting modules.

#### 9. *Surface texture:*

The restorations fitting appears better in smooth tooth preparation (34, 35). The retention of zinc phosphate cement is increased by surface roughness (35-41); its effect has not been as definitely determined with adhesive cements.

Another criterion was added for the assessment:

#### 10. *Lesion of the proximal teeth.*

The grading sheet contains ten criteria above-mentioned, associated with a specific point value and added together to generate the total score. These criteria appear in rows, while the associated letter grades (A, B, C, D and F) appear in columns. There are point values for letter grades on each criterion: A=5, B=4, C=3, D=2, F=0. The total score is the sum of the all points in the columns.

After each student completed the first tooth, performed with a standard procedure, the second Author (GR) has given to everyone an identification number and each tooth was placed into a sealed envelope. The identification numbers were assigned progressively from the first student to finish (id n° 1) to the last one (id n° 24). After each student completed the second tooth, performed with the new technique, the same Author has given to every student an identification letter and each tooth was placed in a different sealed envelope. The identification letters were assigned progressively from the first student to finish (id letter A) to the last (id letter X) in the same way for the identification numbers above-mentioned. Therefore, every student had a double code with a number and a letter (i.e. 1F). Next, the typodonts were given to the evaluator, who was blinded to the student's identity.

### Statistical analysis

A specific statistical software (IBM SPSS V10 Statistics, IBM, Armonk, USA) was used to analyze the data. Descriptive statistics (mean, frequency, range, standard deviations) were computed for each group of students, a T test was performed with a significant P value < 0.05.

### Results

A statistically significant difference between the two techniques was found in 8 out of 10 criteria: only "surface texture" and "line angle form" had p value > 0.05.

The new technique showed higher values (p<0.05) in 7 criteria, while the conventional technique had better results in just 1 criterion ("lesion of the proximal teeth").

Moreover, the total sum of values was higher for the new technique compared to the conventional technique (p<0.05). Data were summarized in Table 1.

Table 1. Assessment criteria.

Assessment criteria	Conventional technique	New technique	P value
Total occlusal convergence	3.82 ± 0.43	4.23±0.78	<0.05
Occlusocervical dimension	3.67 ± 0.67	4.04±0.75	<0.05
Occlusocervical / faciolingual dimension	3.87 ± 0.54	4.12±0.67	<0.05
Circumferential morphology	3.64 ± 0.78	4.25±0.6	<0.05
Finish line location	3.84 ± 0.77	4.21±0.56	<0.05
Finish line form and depth	3.77 ± 0.69	4.33±0.63	<0.05
Axial and occlusal reduction depths	3.93 ± 0.52	4.37±0.62	<0.05
Line angle form	3.83 ± 0.63	4.08±0.65	>0.05
Surface texture	3.81 ± 0.83	3.78±0.81	>0.05
Lesion of the proximal teeth	3.94 ± 0.57	3.79±0.56	<0.05
Total	38.12 ± 5.18	41.2± 3.98	<0.05

## Discussion

According to our results, the new preparation technique is more predictable than the conventional technique for no experienced doctors. The reason is that results are less dependent on manual abilities and personal experience. This study has shown benefits in control of depth and direction of tooth tissue removal as well as a better definition of the tooth finishing line.

The total occlusal convergence (TOC) is an essential criterion to be considered in tooth preparation. Okuyama et al. (42) made a quantitative evaluation of axial wall taper in artificial teeth prepared by pre-clinical students. After a fixed prosthodontics course, they have been instructed to reduce 54 artificial teeth for complete cast restorations. Statistically significant higher TOC than required have been detected. The greatest differences were produced in the vestibular region with a mean taper value of 21.7° instead of 2-5° required. Similarly, Aleisa et al. (43) evaluated 355 tooth preparation for fixed prosthesis carried out by final year undergraduate dental students. Only 32.7% of the preparations have been included inside the total occlusal convergence range recommended by the Authors. The above mentioned studies demonstrate a difficult taper control by students. According to our study, the novel technique shows more predictable results regarding the management of the angle of convergence.

Another important element of tooth preparation is the reduction depth. Indeed, is necessary to make adequate space for the restoration materials. Belinda et al. (44) evaluated 63 single complete gold crown and 151 single ceramometal crown preparations performed by dental students. They found a generally inadequate reduction as well as greater axial convergence angles than recommended. The presence of stopping surfaces on the bur facilitates reliable outcomes for the new technique.

The stump finished with the new technique have shown statistically significant higher results. On the other side, the impossibility to vary the preparation depth as well as the only chance to finish with a 90° shoulder could be a limitation. The dentist should use this technique only in well-defined clinical situations. The novel technique may be a valuable option in tooth preparation parti-

cularly for neophyte dentists: they can use it as a training procedure in their learning curve. It could be also possible the use of the technique in combination with other methods. Hence, due to the small size of the sample (N students = 24, N teeth = 48), which could be affected by selection and information biases, these data need to be evaluated carefully, however the novel technique is a valid alternative in the landscape of fixed prosthodontic preparation techniques.

## Conflict of interest

No potential conflict of interest relevant to the study was reported.

## References

- Castellani D. La preparazione dei pilastri per corone in metal ceramica. Bologna: Edizioni Martina, 2015.
- Shillingburg HT, Hobo S, Whitsett LD, Jacobi R, Brackett SE. Fundamentals of fixed prosthodontics. 3rd ed. Chicago, IL: Quintessence Publishing Co, 1997.
- Goodacre CJ, Compagni WV, Aquilino SA. Tooth preparations for complete crowns: An art form based on scientific principles. *J Prosthet Dent.* 2011 Apr;85(4):363-76.
- Parker MH, Calverley MJ, Gardner FM, Gunderson RB. New guidelines for preparation taper. *J Prosthodont.* 1993;2:61-6.
- Preston JD. Rational approach for tooth preparation to ceramo-metal restoration. *Dent Clin North Am.* 1977;21:683-698.
- Miller L. A clinician's interpretation of tooth preparations and the design of metal substructures for metal-ceramic restorations in McLean JW (ed): *Dental Ceramics; Proceedings of the First International Symposium on Ceramics.* Chicago, Quintessence Publ Co. 1983;173-206.
- Farah JW, Craig RG, Payton FA. Experimental stress analysis of a restored axisymmetric first molar. *J Dent Res.* 1974;53:859-866.
- Maxwell AW, Blank LW, Pelleu GB Jr. Effect of crown preparation height on the retention and resistance of gold castings. *Gen Dent.* 1990;38:200-2.
- Woolsey GD, Matich JA. The effect of axial grooves on the resistance form of cast restorations. *J Am Dent Assoc.* 1978;97:978-80.
- Hegdahl T, Silness J. Preparation areas resisting displacement of artificial crowns. *J Oral Rehabil.* 1977;4:201-7.

11. Waerhaug J. Histologic considerations which govern where the margins of restorations should be located in relation to the gingiva. *Dent Clin North Am.* 1960;4:161-76.
12. Karlsen K. Gingival reactions to dental restorations. *Acta Odontol Scand.* 1970;28:895-904.
13. Marcum JS. The effect of crown marginal depth upon gingival tissue. *J Prosthet Dent.* 1967;17:479-87.
14. Larato DC. The effect of crown margin extension on gingival inflammation. *J South Calif Dent Assoc.* 1969;37:476-8.
15. Bergman B, Hugoson A, Olsson CO. Periodontal and prosthetic conditions in patients treated with removable partial dentures and artificial crowns. A longitudinal two-year study. *Acta Odontol Scand.* 1971;29:621-38.
16. Renggli HH, Regolati B. Gingival inflammation and plaque accumulation by well-adapted supragingival and subgingival proximal restorations. *Helv Odontol Acta.* 1962;16:99-101.
17. Valderhaug J, Birkeland JM. Periodontal conditions in patients 5 years following insertion of fixed prostheses. Pocket depth and loss of attachment. *J Oral Rehabil.* 1976;3:237-43.
18. Newcomb GM. The relationship between the location of subgingival crown margins and gingival inflammation. *J Periodontol.* 1974;45:151-4.
19. Jameson LM. Comparison of the volume of crevicular fluid from restored and nonrestored teeth. *J Prosthet Dent.* 1979;41:209-14.
20. Nevins M. Attached gingival-mucogingival therapy and restorative dentistry. *Int J Periodontics Restorative Dent.* 1986;6:9-27.
21. Carnevale G, Sterrantino SF, Di Febo G. Soft and hard tissue wound healing following tooth preparation to the alveolar crest. *Int J Periodontics Restorative Dent.* 1983;3:36-53.
22. Tarnow D, Stahl SS, Magner A, Zamzok J. Human gingival attachment responses to subgingival crown placement. Marginal remodelling. *J Clin Periodontol.* 1986;13:563-9.
23. Dykema RW, Goodacre CJ, Phillips RW. Johnston's modern practice in fixed prosthodontics. 4th ed. Philadelphia, PA: WB Saunders. 1986;24, 36-9, 249-55, 277-84.
24. Rosenstiel SF, Land MF, Fujimoto J. Contemporary fixed prosthodontics. 2nd ed. St. Louis, MO: Mosby-Year Book. 1995;137-8, 170-3, 184-5, 229.
25. Richter-Snapp K, Aquilino SA, Svare CW, Turner KA. Change in marginal fit as related to margin design, alloy type, and porcelain proximity in porcelain-fused-to-metal restorations. *J Prosthet Dent.* 1988;60:435-9.
26. Syu JZ, Byrne G, Laub LW, Land MF. Influence of finish-line geometry on the fit of crowns. *Int J Prosthodont.* 1993;6:25-30.
27. Bernal G, Jones RM, Brown DT, Munoz CA, Goodacre CJ. The effect of finish line form and luting agent on the breaking strength of Dicor crowns. *Int J Prosthodont.* 1993;6:286-90.
28. Malament KA, Socransky SS. Survival of Dicor glass-ceramic dental restorations over 14 years. Part I. Survival of Dicor complete coverage restorations and effect of internal surface acid etching, tooth position, gender, and age. *J Prosthet Dent.* 1999;81:23-32.
29. Douglas RD, Przybylska M. Predicting porcelain thickness required for dental shade matches. *J Prosthet Dent.* 1999;82:143-9.
30. Doyle MG, Goodacre CJ, Munoz CA, Andres CJ. The effect of tooth preparation design on the breaking strength of Dicor crowns: 3. *Int J Prosthodont.* 1990;3:327-40.
31. Craig RG, el-Ebrashi MK, Peyton FA. Experimental stress analysis of dental restorations. Part II. Two-dimensional photoelastic stress analysis of crowns. *J Prosthet Dent.* 1967;17:292-302.
32. Walton CB, Leven MM. A preliminary report of photoelastic tests of strain within jacket crowns. *J Am Dent Assoc.* 1955;50:44-8.
33. Nicholls JL. Crown retention. I. Stress analysis of symmetric restorations. *J Prosthet Dent.* 1974;31:179-84.
34. Charbeneau GT, Peyton FA. Some effects of cavity instrumentation on the adaptation of gold castings and amalgam. *J Prosthet Dent.* 1958;8:514-25.
35. Tjan AHL, Sarkissian R. Effect of preparation finish on retention and fit of complete crowns. *J Prosthet Dent.* 1986;56:283-8.
36. Tuntiprawon M. Effect of surface roughness on marginal seating and retention of complete metal crowns. *J Prosthet Dent.* 1999;81:142-7.
37. Felton DA, Kanoy BE, White JT. The effect of surface roughness of crown preparations on retention of cemented castings. *J Prosthet Dent.* 1987;58:292-6.
38. Oilo G, Jorgensen KD. The influence of surface roughness on the retentive ability of two dental luting cements. *J Oral Rehabil.* 1978;5:377-89.
39. Juntavee N, Millstein PL. Effect of surface roughness and cement space on crown retention. *J Prosthet Dent.* 1992;68:482-6.
40. Witwer DJ, Storey RJ, von Fraunhofer JA. The effects of surface texture and grooving on the retention of cast crowns. *J Prosthet Dent.* 1986;56:421-4.
41. Ayad MF, Rosenstiel SF, Salama M. Influence of tooth surface roughness and type of cement on retention of complete cast crowns. *J Prosthet Dent.* 1997;77:116-21.
42. Okuyama Y, Kasahara S, Kimura K. Quantitative evaluation of axial walltaper in prepared artificial teeth. *J Oral Sci.* 2005;47:129-33.
43. Aleisa K, Al-Dwairi ZN, Alwazzan K, Al-Moither M, Al-Shammari M, Lynch E. Convergence angles of clinical tooth preparations achieved by dental students at King Saud University, Saudi Arabia. *J Dent Educ.* 2013;77:1154-8.
44. Belinda K, Poon M, Smales RJ. Assessment of clinical preparations for single gold and ceramometal crowns. *Quintessence Int.* 2001;32:603-10.